

## Xanthogranulomatous Pyelonephritis (XGPN) Presenting as Renal Lump in Infant: Rare Presentation

Rahul Ghule, Ram Daga,  
Jaydeep Date, Sujit Joshi,  
Subodh Shivde

Deenanath Mangeshkar Hospital and  
Research Centre, Pune, Maharashtra,  
India

### Abstract

**Background:** Xanthogranulomatous pyelonephritis (XGPN) is an unusual suppurative granulomatous reaction to chronic renal infection. It usually presents with symptoms of infections. It is rare entity especially in childhood.

**Case:** We are reporting case of xanthogranulomatous pyelonephritis in 2 month male baby presented as left renal mass without signs of infections. On imaging it shows multicystic, heterogeneous, non-enhancing left renal mass.

**Conclusion:** XGPN, itself is a rare entity presenting in infant/childhood of which presentation solely as renal lump without any signs and symptoms of urosepsis, UTI. Hence even in neonate/childhood one should consider it as one of D/D presenting as renal mass.

**Keywords:** Xanthogranulomatous pyelonephritis (XGPN); Renal lump; Urosepsis

### Corresponding Author:

Rahul Ghule

Deenanath Mangeshkar Hospital and  
Research Centre, Pune, Maharashtra, India

✉ drrahulghule@gmail.com

Tel: +918308804098

**Received:** October 22, 2015, **Accepted:** November 11, 2015, **Published:** November 16, 2015

## Introduction

Xanthogranulomatous pyelonephritis (XGPN) is rare variant of chronic pyelonephritis. The most common associated factors are urinary tract obstruction and infection. It is presumed to be related to chronic bacterial infection, renal or lymphatic obstruction, alterations in lipid metabolism or an ineffective immune response to infection, nephrolithiasis [1]. It rarely appears in childhood. A very few cases in neonatal period have been reported in literature so far. It is important to recognize this rare entity in children because it may be confused with childhood renal malignancies particularly Wilm's tumors [1].

## Case

2 months old male baby presented with lump in left lumbar region, denied history of fever, weight loss and urinary infection. Haemogram was normal, no leukocytosis, occasional pus cells in urine analysis, no growth on urine culture. On examination, nutrition was good, per abdominal large lump palpable in left lumbar, iliac, extending to umbilical region. Systemic examination was normal. Ultrasound suggestive of large left renal mass with cystic/solid component, contrasts enhanced CT scan suggestive of multicystic, heterogeneous; non-enhancing left renal mass. Since a differential of renal malignancy was considered, patient

underwent left nephrectomy. Histopathology was suggestive of xanthogranulomatous pyelonephritis. After 2 years, baby had multiple admissions for urinary infection. On evaluation, voiding cystourethrogram s/o vesicoureteric reflux on left side with dilation remaining ureteral stump (**Figure 1-3**).

## Discussion

XGPN is an atypical form of severe chronic renal parenchymal infection [2]. The first descriptions of the distinctive gross and macroscopic features of this disease were made by Schlagenhaufen in 1916 [3-5], but it was Oberlin who introduced the term XGPN in 1935 [5]. In 1978, Malek and Elder classified and staged the disease [6]. The first pediatric case was described in 1963 by Avnet and Friedenber [5, 7, 8]. It is an uncommon entity, accounting for between 0.6% of histologically documented cases of chronic pyelonephritis [9]. A review of recently published data indicates that about 80 cases of XGPN have been reported in pediatric age [10]. The earliest age of presentation reported so far ranges from 21 days in English literature by Youngson GG [11], 48 days in Japanese literature by Yazaki T [12], 40 days old by Anand Upasani et al [13]. We are reporting case of 60 days (2 month) male baby.

XGPN is classified into three stages: stage I - the lesion is

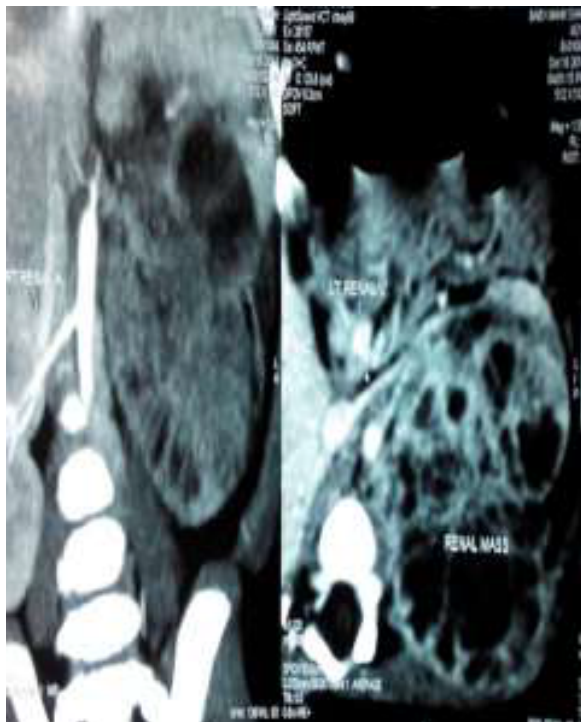

Figure 1 CECT (coronal view).

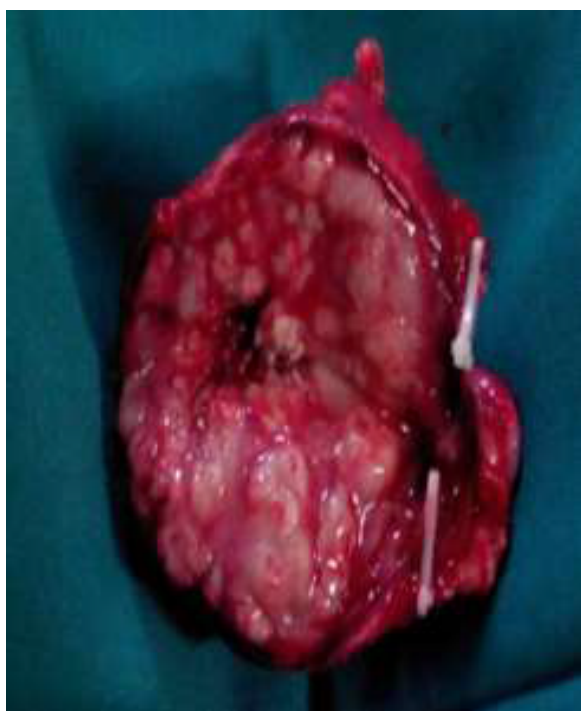

Figure 2 Cut section of specimen.

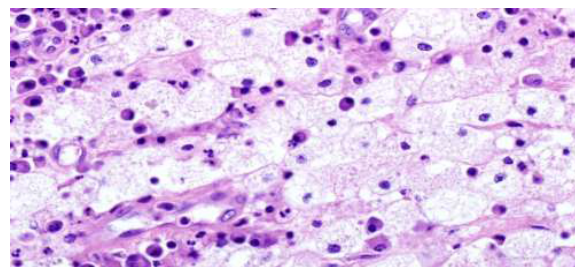


Figure 3 Cut Histopathology of XGPN. section of specimen.

confined to the kidney (nephric), stage II - when it extends to Gerota's space (perinephric) and stage III - the extension to the perinephric space or retroperitoneal structures (paranephric) [14]. Both diffuse and focal forms of the disease have been reported, with the diffuse form being more common [14]. In children, the disease most frequently occurs below 8 years of age with male predominance affecting left kidney predominantly [10]. In adults, females are affected more than males and right kidney has been noted to be involved more often than the left [10]. Presentation is varied from sepsis to asymptomatic renal lump but most of these children present with symptoms of chronic infection, like recurrent fever, weight loss, pallor and failure to thrive etc. Although bacterial culture from urine reveals *E. coli*, *Proteus* as the most common offending organism [2, 15], but in our case it was sterile. Radiological features are not specific and mimic neoplasia. It is important to consider XGPN in order to avoid needless preoperative irradiation of a large abdominal mass, extensive lymph node dissection, or administration of myelosuppressive agents at the time of operation [16].

The present case is unique in way that, 2 month old male baby presented with left renal mass without any sign and symptoms of urosepsis, UTI. Urine was normal, there was no leukocytosis, radiology (ultrasound/CECT) suggestive of left renal mass without any peculiar feature of particular pathology and hence the presumptive diagnosis of renal neoplasm was made. In view of renal neoplasm, left radical nephrectomy was done. Final diagnosis was settled on histopathology as XGPN. After extensive search of literature, till now there are only 8-10 cases reported as XGPN presenting as renal mass or pseudotumour in infants.

## Summary

XGPN is a relatively rare entity especially in infant. As it can be presented as renal lump without signs of infection, it should be included in the differential diagnosis of children with a renal mass. As the prognosis in adequately treated XGP is quite good, a clinical awareness and a high index of suspicion are required to achieve the correct preoperative diagnosis and appropriate management.

## References

- 1 Alberto Berenguer, Carla Pilar, Michelle Smit, José Luis Nunes (2012) Xanthogranulomatous pyelonephritis presenting as a pseudotumour in a 5-year-old boy. *BMJ Case Reports*.
- 2 Quinn FM, Dick AC, Corbally MT, McDermott MB, Guiney EJ (1999) Xanthogranulomatous pyelonephritis in childhood. *Arch Dis Child* 81: 483-486.
- 3 Li L, Parwani AV (2011) Xanthogranulomatous pyelonephritis. *Arch Pathol Lab Med* 135: 671-674.
- 4 Korkes F, Favoretto RL, BrÃglio M, Silva CA, Castro MG, et al. (2008) Xanthogranulomatous pyelonephritis: clinical experience with 41 cases. *Urology* 71: 178-180.
- 5 Zugor V, Schott GE, Labanaris AP (2007) Xanthogranulomatous pyelonephritis in childhood: a critical analysis of 10 cases and of the literature. *Urology* 70: 157-160.
- 6 Malek RS, Elder JS (1978) Xanthogranulomatous pyelonephritis: a critical analysis of 26 cases and of the literature. *J Urol* 119: 589-593.
- 7 Avnet NL, Roberts TW, Goldberg HR (1963) Tumefactive xanthogranulomatous pyelonephritis. *Am J Roentgenol Radium Ther Nucl Med* 90: 89-96.
- 8 Friedenber MJ, Spjut HJ (1963) Xanthogranulomatous pyelonephritis. *Am J Roentgenol Radium Ther Nucl Med* 90: 97-108.
- 9 Li L, Parwani AV (2011) Xanthogranulomatous pyelonephritis. *Arch Pathol Lab Med* 135: 671-674.
- 10 Nandedkar Shirish S, Malukani Kamal, Sakhi Pramod (2014) Xanthogranulomatous pyelonephritis masquerading as a tumor in an infant. *Indian J Urol* 30: 354-356.
- 11 Youngson GG, Gray ES (1990) Neonatal xanthogranulomatous pyelonephritis. *Br J Urol* 65: 541-542.
- 12 Yazaki T, Ishikawa S, Ogawa Y, Takahashi S, Nemoto S, et al. (1982) Xanthogranulomatous pyelonephritis in childhood: case report and review of English and Japanese literature. *J Urol* 127: 80-83.
- 13 Upasani A, Panwar J, Chandna S, Patel D (2012) Xanthogranulomatous pyelonephritis in early infancy. *BMJ Case Rep* 2012.
- 14 Gupta S, Araya CE, Dharnidharka VR (2010) Xanthogranulomatous pyelonephritis in pediatric patients: case report and review of literature. *J Pediatr Urol* 6: 355-358.
- 15 Watson AR, Marsden HB, Lendon M, Jones PH (1982) Renal pseudotumours caused by xanthogranulomatous pyelonephritis. *Arch Dis Child* 57: 635-637.
- 16 Fahr K, Oppermann HC, SchÃrker K, Greinacher I (1979) Xanthogranulomatous pyelonephritis in childhood. Report of three cases and a review of the literature. *Pediatr Radiol* 8: 10-16.