

## True Duplicate Bladder Exstrophy

Sajad Ahmad Wani,  
Nisar Ahmad Bhat,  
Gowher Nazir Mufti and  
Aejaz Ahsan Baba

SR Department of Paediatric Surgery, SKIMS  
Soura, Srinagar, Jammu and Kashmir, India

**Corresponding Author:**  
Sajad Ahmad Wani

Department of Paediatric Surgery, SKIMS  
Soura, Srinagar, Jammu and Kashmir, India.

✉ ahmadsajadwani@gmail.com

Tel: 9596310531

**Citation:** Wani SA, Bhat NA, Mufti GN, et al.  
True Duplicate Bladder Exstrophy. J Rare Dis  
Diagn Ther. 2015, 1:3.

### Abstract

A three months male child was admitted in our department as a rare variant of bladder exstrophy (true duplicate bladder exstrophy). There are only 8 cases of this variant reported in the literature so far, we report an additional case to add the scarce literature.

**Keywords:** True duplicate exstrophy; Bladder exstrophy; Exstrophy variants

**Received:** November 06, 2015, **Accepted:** November 14, 2015, **Published:** November 21, 2015

### Introduction

Bladder exstrophy is a rare congenital anomaly and classical bladder exstrophy is the most common. Rare variants of exstrophy bladder constitutes only 10% of cases and duplicate exstrophy is one of the rarest variant of which only 24 cases have been reported [1]. Patients present with patch of exstrophic bladder just below the umbilicus with either a normal or smaller than normal complete bladder underneath and diastasis of symphysis pubis. The duplicated extroverted patch of bladder mucosa is dry and does not receive ureters. True duplicate exstrophy is very rare variant of bladder exstrophy and only 8 cases have been reported, we present another case to add to the literature.

### Case Report

Three months full term male child was admitted in our department as a case of bladder exstrophy. On examination, dry bladder mucosa was exposed just below the umbilicus with separation of rectus. Penile length was normal with orthotopic meatus but poorly developed corporal bodies (**Figure 1**). Child was passing urine normally. Both the testicles were palpable in scrotum and there was no other anomaly present. Widening of symphysis pubis was seen on X-ray. All baseline investigations were normal.

Dry exstrophied bladder mucosa was excised and the abdominal wall defect was closed (**Figure 2**). Postoperative period was uneventful and baby was discharged on third postoperative day. HPE revealed transitional cell lining of the respected specimen.

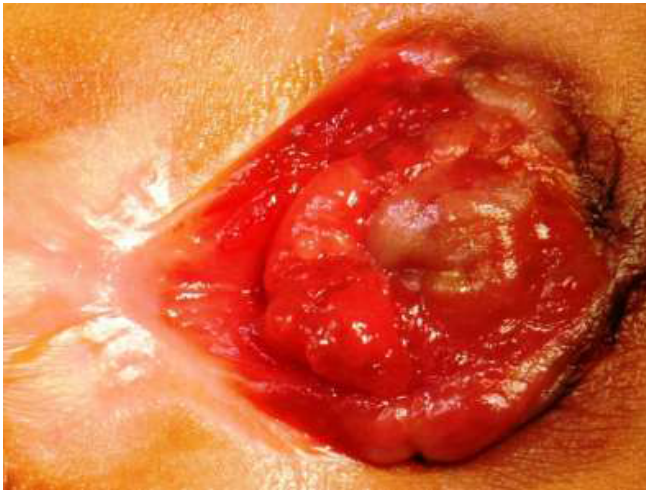
### Discussion

Marshall and Muecke defined the true bladder duplicate exstrophy as a suprapubic exstrophic mucosal plate with subjacent normal

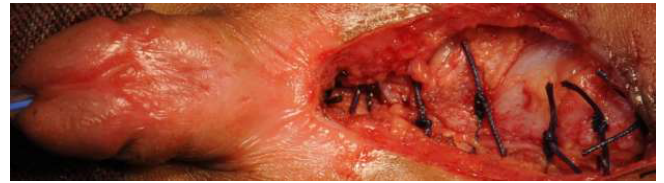or near normal bladder with relatively normal phallus. Epispadias is absent and exstrophic plate does not receive ureters [2]. Embryologically if the superior vesical fissure fuses, an overfilling bladder mucosal plate presents as duplication of bladder [3].

Duplication exstrophy is of two types, the first is suprapubic exstrophic mucosal plate and a covered bladder as in our case. The second type is associated with classical findings of exstrophy complex [4]. The embryological explanation of the numerous variations in the exstrophy complex suggests that the urogenital part of the cloacal membrane occupies cranial position to the genital primordial. During development the cloacal membrane prevents in growth of mesoderm towards the midline and preventing its insertion between the ectodermal and endodermal layers. Thus, number of variants of exstrophy complex can develop. Bladder duplication may have associated duplication of ureters, vagina, bifid clitoris, caecum, double appendix, ARM, and spinal dysraphism [5].

The operative procedure is simple in such cases. In our case, excision of dry exstrophied bladder mucosa with closure of abdominal wall defect was done. Postoperative period was uneventful and patient is doing well in follow up. Our case was identical to cases reported by other authors [2,3,6].



**Figure 1** Dry bladder mucosa exposed just below the umbilicus with separation of rectus.



**Figure 2** Excised dry exstrophied bladder mucosa with closure of abdominal wall defect.

## References

- 1 Andiran F, Tanyel FC (1999) Duplicate exstrophy of the bladder. *J Pediatr Surg* 34: 626-627.
- 2 Marshall VF, Muecke EC (1962) Variations in exstrophy of the bladder. *J Urol* 88: 766-776.
- 3 Mathur P, Panwar RS, Kumari K, Khamesra HL (2002) True duplicate bladder exstrophy: a case report. *Pediatr Surg Int* 18: 204-205.
- 4 Sheldon C A, McLorie G A, Khoury A, Churchill BM (1990) Duplicate bladder exstrophy: a new variant of clinical and embryological significance. *J Urol* 144: 334-336.
- 5 Chadha R, Sharma A, Bagga D, Mahajan JK (1999) Covered exstrophy with incomplete duplication of the bladder. *Pediatr Surg Int* 15: 422-424.
- 6 Ellis DG (1971) Duplicate exstrophy of the bladder. *J Urol* 106: 295-297.