

Obstructive Sleep Apnea in Patients with MPS: Need for Anatomic Evaluation of the Airway

Rachna Wadia,
Edward Fong and
Paul Harmatz

UCSF Benioff Children's Hospital Oakland,
Oakland, CA, USA

Abstract

The mucopolysaccharidoses are a group of inherited, progressive disorders caused by mutations in the genes coding for lysosomal enzymes required to break down glycosaminoglycans (GAGs). GAGs are long-chain complex carbohydrates that are key components to the ground substance of connective tissue, nuclear, and cell membranes. This leads to a multitude of signs and symptoms that worsen with age. Respiratory involvement is common, and is usually manifested by recurrent respiratory infections, upper and lower airway obstruction, restrictive lung disease, sleep disordered breathing (SDB) and exertional dyspnea. The presence of obstructive sleep apnea (OSA) not easily amenable to non-invasive positive pressure ventilation (NIPPV) should prompt one to perform an airway evaluation to look for external compression versus intrinsic malacia of the airways, as their management is different. We describe two cases that illustrate differences in evaluation depending on mechanism of their airway obstruction. The first patient with Morquio A syndrome (MPS IVA) and OSA was found to have compression of his trachea by his innominate artery and thyroid gland requiring surgical management. The second patient with Hunter's syndrome (MPS II) and OSA were found to have intrinsic malacia of the airways requiring only bilevel positive pressure ventilation (BiPAP).

keywords: Airway evaluation; Morquio syndrome; Mucopolysaccharidoses; Obstructive sleep apnea; Tracheal obstruction; Innominate artery compression

Abbreviations: BiPAP: Bilevel Positive Airway Pressure; CTA: Computed Tomography Angiogram; GAGs: Glycosaminoglycans; MPS: Mucopolysaccharidoses; MRI: Magnetic Resonance Imaging; NIPPV: Non-invasive Positive Pressure Ventilation; OSA: Obstructive Sleep Apnea; PSG: Polysomnogram; SDB: Sleep Disordered Breathing

Received: October 23, 2015; **Accepted:** November 24, 2015; **Published:** November 30, 2015

Introduction

The mucopolysaccharidoses are a group of inherited, progressive disorders caused by mutations in the genes coding for lysosomal enzymes required to break down glycosaminoglycans (GAGs). GAGs are long-chain complex carbohydrates that are key components to the ground substance of connective tissue, nuclear, and cell membranes [1-5]. This leads to a multitude of signs and symptoms that worsen with age [1, 6]. Respiratory involvement is common, and is usually manifested by recurrent respiratory infections, upper and lower airway obstruction, restrictive lung disease, sleep disordered breathing (SDB) and exertional dyspnea [7].

Manifestations of MPS are first seen around 1-4 years of age with slow growth and abnormalities in gait, hip dysplasia, genu valgum, kyphosis, joint contractures, chest wall shape, multiple hernias, and frequent respiratory or ear infections as common presenting findings [3, 8, 9]. Disease severity depends on the amount of enzyme activity present. Skeletal malformations, most commonly kyphoscoliosis, chest wall deformity, and poor spine growth, along with enlarged liver and spleen, often lead to restrictive respiratory mechanics [7]. Narrowing of the larynx and upper airway as well as an abnormally shaped trachea or glottis may occur [2, 4, 6, 10]. Tracheal distortion is common secondary

Corresponding Author: Rachna Wadia

UCSF Benioff Children's Hospital Oakland,
Oakland, CA 94609, USA.

✉ rawadia@mail.choc.org

Tel: 510-428-3305

Citation: Wadia R, Fong E, Harmatz P. Obstructive Sleep Apnea in Patients with MPS: Need for Anatomic Evaluation of the Airway. *J Rare Dis Diagn Ther.* 2015, 1:3.

to short spinal height [11]. Tracheo- and bronchomalacia may be present as well [12]. The prevalence of OSA in the MPS population is quite high ranging from 69-95% [13-15], and its cause can be multifactorial: macroglossia, adenotonsillar hypertrophy, bending of the trachea secondary to small thoracic cage, and GAG deposition in the tracheobronchial mucosa [13].

Enzyme replacement therapy (ERT) has now been approved for MPS I, II, IV, and VI [16-19]. With ERT there has been some evidence of improvement in lung function as measured by forced vital capacity (FVC) [20, 21]. There has only been one reported sleep apnea clinical trial in MPS patients while on ERT, in those with MPS I receiving laronidase. They found that in those who had sleep apnea at baseline, they did have a significant reduction in their apnea hypopnea index (AHI) by 6 events per hour [22].

We use two cases to describe the work-up and management of MPS patients with airway external compression vs. intrinsic malacia.

Case 1

Teen boy with classical Morquio A syndrome (MPS IVA, OMIM #253000), which is an autosomal recessive disorder caused by a deficiency of the lysosomal enzyme N-acetyl-galactosamine-6-sulfatase GALNS causing a build-up of keratin and chondroitin-6-sulfate [3, 5], presented with SBD and exertional dyspnea. The patient had been participating in a clinical trial of elosulfase alfa enzyme replacement therapy (BioMarin Pharmaceutical). He had previously undergone 5+ orthopedic surgeries for spine stabilization and cord decompression, hip dysplasia, and genu valgum, but was noted on one of his last procedures at the age of 15 to have an obstructed trachea. After the tracheal obstruction was noted at anesthesia, he had a polysomnogram (PSG) revealing severe OSA (AHI 24.7) that was only partially resolved with BiPAP. Lung function on spirometry demonstrated progressive worsening of obstruction over the year prior to the PSG. The patient also provided a history of increased fatigue and shortness of breath with exercise (**Table 1**).

Imaging (3-dimensional reconstruction CT angiography (CTA), dynamic chest MRI, and echocardiogram) demonstrated: 1) Narrowing of the trachea at the thoracic inlet (3.3 cm) secondary to external compression by a tortuous right innominate artery, and thyroid gland, exacerbated by a retroflexed manubrium; 2) A bent/distorted trachea secondary to a shortened spine. Flexible bronchoscopy revealed multiple areas of compression vs. collapse of the airways at the level of the hypopharynx, larynx, subglottic space, and mid-distal trachea. The airways mucosa revealed a paucity of GAG deposits. He was referred to Alfred I. duPont Hospital for Children for surgical management of his tracheal compression (**Figure 1**).

Table 1 Pulmonary Function Testing for MPS IVA patient.

| | 14 yr 4 mo | 14 yr 10 mo | 15 yr 6 mo | 15 yr 9 mo | 16 yr 1 mo | 16 yr 3 mo |
|-----------------------|------------|-------------|------------|------------|------------|------------|
| FVC (liters) | 1.52 | 1.62 | 1.62 | 1.34 | 1.72 | 1.78 |
| FEV1 (liters) | 1.13 | 1.10 | 0.96 | 0.75 | 0.85 | 0.71 |
| FEV1/FVC (liters/sec) | 75 | 72 | 59 | 56 | 50 | 40 |

Case 2

Teen boy with attenuated Hunter syndrome (MPS II, OMIM# 309900) an x-linked recessive disorder caused by the deficiency of lysosomal enzyme iduronate-2-sulfate (I2S) causing a build-up of heparan and dermatan sulphate in the body [9, 23], was noted to have progressive exertional dyspnea and snoring along with choking spells with sleep in the past year. He had been on idursulfase ERT (Shire Human Genetics Therapies, Inc.) for 12 years. During a surgery for tendon release and synovectomy of his left carpal tunnel, he was noted to have stenosis of his subglottic area on intubation. He underwent flexible bronchoscopy and was found to have multi-level compression/collapse of his airway at the level of the subglottic space, proximal and distal trachea, bronchus intermedius, and left mainstem. The trachea completely collapsed on the bronchoscope with each exhalation making it difficult to move the scope. The left mainstem was almost completely collapsed/compressed. CT scan revealed a generous pulmonary artery, but no source of external compression. PSG revealed moderate sleep apnea (AHI 8), which was alleviated with BiPAP 8/4. The low pressures were consistent with the diagnosis of intrinsic malacia of the airways (**Figure 2**).

Discussion

These 2 cases illustrate the importance of a systematic airway evaluation with flexible bronchoscopy, CTA with 3D rendering, lung function testing, and PSG to see how to best manage the patient's airway obstruction. We described two teen boys, one with MPS IVA and one with MPS II. In both cases, they presented with dyspnea on exertion and SDB, however, results of their evaluation differed greatly and dictated different management.

Flexible bronchoscopy allows one to not only visualize the airway, but assess its dynamics. Both patients described were found to have multiple levels of collapse vs. compression on flexible bronchoscopy. Each patient's trachea was distorted due to the length of the trachea bending to fit in the short thoracic cage. During respiration, the obstruction of case 1 (MPS IVA) just distal to the subglottic space did not change significantly, whereas the obstruction of case 2 (MPS II) was very dynamic (almost complete collapse of the trachea with each exhalation); thus consistent with a fixed external obstruction in case 1.

CTA with 3D rendering helped us to better understand whether or not there was external compression causing/contributing to the airway obstruction seen on bronchoscopy. In case 1, we were able to see that both the tortuous innominate artery and thyroid were directly compressing the trachea. The other areas of obstruction seen on bronchoscopy were due to the trachea bending to fit in the shortened thoracic cage. Innominate artery compression of the trachea has been well reported for normal

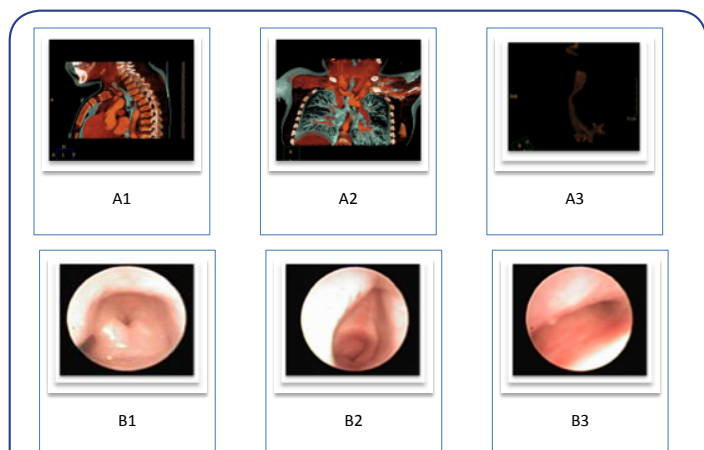


Figure 1 Diagnostic Studies for MPS IVA patient.

- A1. 3D CTA reconstruction sagittal view: Narrowing of the thoracic inlet related to the horizontal orientation of the manubrium and innominate artery compression.
- A2. 3D CTA reconstruction AP view: compression of the proximal trachea by the innominate artery.
- A3. 3D CTA reconstruction: Airway disappears at the subglottic level. There is also mid-distal tracheal narrowing.
- B1. Laryngomalacia on flexible bronchoscopy. Arytenoids appear swollen possibly secondary to GAG deposition
- B2. Flexible bronchoscopic view of severe subglottic obstruction (85-90% obstructed). Only minimal improvement with PEEP 12 cm H₂O.
- B3. Flexible bronchoscopic view of proximal trachea revealing mid-tracheal collapse.

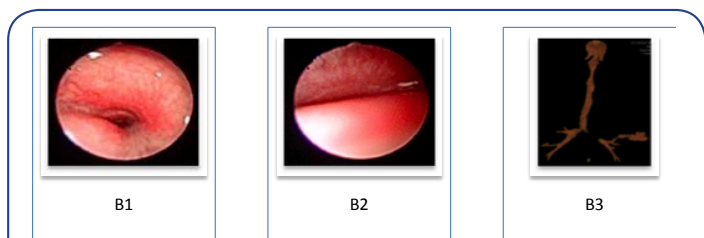


Figure 2 Diagnostic studies for MPS II patient.

- A. Flexible bronchoscopic view just below the subglottic space revealing almost complete obstruction of the airway.
- B. Flexible bronchoscopic view of complete collapse of the mid-trachea during exhalation.
- C. 3D CTA of airways: narrowing at the subglottic level, some narrowing in mid trachea, and complete obliteration of left mainstem bronchus.

individuals from birth to 3 years, and some up to 12 years of age, but rare thereafter [24]. These authors could not find any reported cases of MPS affected adolescents with external compression of the airway. In case 2, the CT revealed significant collapse of the trachea and left main stem bronchus, but there were no external structures compressing the airway. Thus, it was thought that in addition to the bending of the trachea to fit in the thoracic cage, there was also intrinsic malacia of the airways.

Lung function testing in both cases proved to be valuable. Case

1 (MPS IVA) had evidence of worsening obstruction. It is worth noting that while his FVC was improving as expected with ERT, the FEV1/FVC ratio was declining to as low as 0.40. For case 2 (MPS II), lung function testing revealed a low FEV1/FVC ratio of 0.56, which corresponded to the obstruction seen on flexible bronchoscopy. As commonly used in MPS cases, the FVC alone did not reveal obstruction, but the FEV1/FVC ratio clearly revealed it. In the International Guidelines for the Management and Treatment of Morquio A Syndrome, it is recommended to perform FVC at diagnosis and then annually until the patient stops growing or when the patient is on treatment. Once growth has stopped, testing can be reduced to every 2-3 years or sooner if they have respiratory symptoms [25]. These cases illustrate the value of the absolute FEV1/FVC ratio rather than just looking at the FVC alone as obstruction can be missed. If the FEV1/FVC ratio is abnormal, consideration for more frequent lung function monitoring is recommended.

The last diagnostic modality is a PSG. Case 1 (MPS IVA) had severe OSA that was not resolved with BiPAP. This is due to his fixed external compression of his trachea by his innominate artery and thyroid gland. Case 2 (MPS II) had moderate OSA that was easily palliated with low pressures of BiPAP, which is consistent with intrinsic malacia rather than compression.

With the above airway evaluation, case 1 (MPS IVA) was found to have tracheal compression by the innominate artery and thyroid gland that was not amenable to BiPAP treatment. Although he likely has intrinsic airways malacia as well based on flexible bronchoscopy, external compression by the innominate artery is the primary reason his respiratory symptoms were progressing. The 3D chest CTA reconstruction was the critical exam in defining his airway pathology and should be pursued in any patient not responding readily to NIPPV. Although his airway compression might have been improved by tracheostomy placement, this procedure would have placed the patient at high risk for erosion of his airway by the innominate artery exerting pressure against the rigid tracheostomy tube possibly resulting in intra-airway hemorrhage [26]. Surgery appeared to be his best option. The two procedures that may be considered include re-implantation of the innominate artery or pexy of the innominate artery against a resected manubrium / reconstructed anterior chest wall [27, 28]. He would then be a candidate for a tracheostomy tube placement to manage his malacia or be a possible candidate for resection of redundant trachea. NIPPV could also be used post-op to maintain tracheal patency during sleep. He was referred to Alfred I. duPont Hospital for Children for surgical management. This comprehensive airway evaluation can also be generalized to those subjects without MPS as there are rare case reports of older children with a crowded mediastinum with apnea secondary to innominate artery tracheal compression [29], however, to these authors' knowledge, a systemic work-up has yet to be established.

We conclude that 4 diagnostic modalities should be performed (potentially serially) in the MPS patient with exertional dyspnea and progressive OSA to evaluate for airway external compression vs. intrinsic malacia: 1) flexible bronchoscopy, 2) CTA with 3D rendering, 3) PSG, and 4) lung function testing specifically looking at FEV1/FVC to help determine appropriate management.

Financial Disclosure Statement

Paul Harmatz, MD has provided consulting support to BioMarin Pharmaceutical and Shire HGT, and received grant support and honorarium for travel from both BioMarin and Shire. Edward Fong, MD has provided consulting support to BioMarin Pharmaceutical and Gilead Sciences, and received speaker and travel honorarium from BioMarin. The authors confirm independence from the sponsors; the content of the article has not been influenced by the sponsors.

Contributor's Statement

All authors listed have made substantial contributions to conception and design, or acquisition of data, or analysis and interpretation of data. Furthermore, each author was involved in drafting the submitted article or revising it critically for important intellectual content and approving the final version for publication. Each author has agreed to be accountable for all aspects of the work in ensuring that questions related to the accuracy or integrity of any part of the work are appropriately investigated and resolved.

References

- Hendriksz CJ, Harmatz P, Beck M, Jones S, Wood T, et al. (2013) Review of clinical presentation and diagnosis of mucopolysaccharidosis IVA. *Mol Genet Metab* 110: 54-64.
- Morimoto N, Kitamura M, Kosuga M, Okuyama T (2014) CT and endoscopic evaluation of larynx and trachea in mucopolysaccharidoses. *Mol Genet Metab* 112: 154-159.
- Spranger J (2007) Mucopolysaccharidoses. *Vol Nelson Tex*: 620-626.
- Walker R, Belani KG, Braunlin EA, Bruce IA, Hack H, et al. (2013) Anaesthesia and airway management in mucopolysaccharidosis. *J Inherit Metab Dis* 36: 211-219.
- Yasuda E, Fushimi K, Suzuki Y, Shimizu K, Takami T, et al. (2013) Pathogenesis of Morquio A syndrome: an autopsied case reveals systemic storage disorder. *Mol Genet Metab* 109: 301-311.
- Pelley CJ, Kwo J, Hess DR (2007) Tracheomalacia in an adult with respiratory failure and Morquio syndrome. *Respir Care* 52: 278-282.
- Muhlebach MS, Wooten W, Muenzer J (2011) Respiratory manifestations in mucopolysaccharidoses. *Paediatr Respir Rev* 12: 133-138.
- Northover H, Cowie RA, Wraith JE (1996) Mucopolysaccharidosis type IVA (Morquio syndrome): a clinical review. *J Inherit Metab Dis* 19: 357-365.
- Kaur J, Swami AC, Kumar A, Lata S (2012) Anesthetic management of a child with Hunter's syndrome. *J Anaesthesiol Clin Pharmacol* 28: 255-257.
- Muhlebach MS, Shaffer CB, Georges L, Abode K, Muenzer J (2013) Bronchoscopy and airway management in patients with mucopolysaccharidoses (MPS). *Pediatr Pulmonol* 48: 601-607.
- Walker PP, Rose E, Williams JG (2003) Upper airways abnormalities and tracheal problems in Morquio's disease. *Thorax* 58: 458-459.
- Berger KI, Fagondes SC, Giugliani R, Hardy KA, Lee KS, et al. (2013) Respiratory and sleep disorders in mucopolysaccharidosis. *J Inherit Metab Dis* 36: 201-210.
- Lin HY, Chen MR, Lin CC, Chen CP, Lin DS, et al. (2010) Polysomnographic characteristics in patients with mucopolysaccharidoses. *Pediatr Pulmonol* 45: 1205-1212.
- Gonuldas B, Yilmaz T, Sivri HS, Güçer KS, Kılınc K, et al (2014) Mucopolysaccharidosis?: Otolaryngologic findings, obstructive sleep apnea and accumulation of glucosaminoglycans in lymphatic tissue of the upper airway. *Int J Pediatr Otorhinolaryngol* 78: 944-949.
- Moreira GA, Kyosen SO, Patti CL, Martins AM, Tufik S (2014) Prevalence of obstructive sleep apnea in patients with mucopolysaccharidosis types I, II, and VI in a reference center. *Sleep Breath* 18: 791-797.
- FDA (2003) Laronidase Product Approval Information - Licensing Action.
- Citrome L (2010) Iloperidone redux: a dissection of the Drug Approval Package for this newly commercialised second-generation antipsychotic. *Int J Clin Pract* 64: 707-718.
- FDA (2006) Approves First Treatment for Hunter Syndrome.
- FDA (2014) FDA approves Vimizim to treat rare congenital enzyme disorder.
- Harmatz P, Yu ZF, Giugliani R, Schwartz IV, Guffon N, et al. (2010) Enzyme replacement therapy for mucopolysaccharidosis VI: evaluation of long-term pulmonary function in patients treated with recombinant human N-acetylgalactosamine 4-sulfatase. *J Inherit Metab Dis* 33: 51-60.
- Wraith J, Lorne C, Beck M, Kolodny EH, Pastores GM (2004) Enzyme Replacement Therapy For Mucopolysaccharidosis I: A Randomized, Double-Blinded, Placebo-Controlled, Multinational Study Of Recombinant Human A -L-Iduronidase (Laronidase). *J Pediatr* 144: 581-588.
- Muenzer J (2014) Early initiation of enzyme replacement therapy for the mucopolysaccharidoses. *Mol Genet Metab* 111: 63-72.
- Malik V, Nichani J, Rothera MP, Wraith JE, Jones SA, et al. (2013) Tracheostomy in mucopolysaccharidosis type II (Hunter's Syndrome). *Int J Pediatr Otorhinolaryngol* 77: 1204-1208.
- Myer CM 3rd, Wiatrak BJ, Cotton RT, Bove KE, Bailey WW (1989) Innominate artery compression of the trachea: current concepts. *Laryngoscope* 99: 1030-1034.
- Hendriksz CJ, Berger KI, Giugliani R, Harmatz P, Kampmann C, et al. (2015) International guidelines for the management and treatment of Morquio A syndrome. *Am J Med Genet A* 167A: 11-25.
- Jones JW, Reynolds M, Hewitt RL, Drapanas T (1976) Tracheo-innominate artery erosion: Successful surgical management of a devastating complication. *Ann Surg* 184: 194-204.
- Gardella C, Girosi D, Rossi G a, Silvestri M, Tomà P, et al. (2010) Tracheal compression by aberrant innominate artery: clinical presentations in infants and children, indications for surgical correction by aortopexy, and short- and long-term outcome. *J Pediatr Surg* 45: 564-573.
- Grimmer JF, Herway S, Hawkins JA, Park AH, Kouretas PC (2009) Long-term results of innominate artery reimplantation for tracheal compression. *Arch Otolaryngol Head Neck Surg* 135: 80-84.
- Friedman E, Kennedy A, Neitzschman HR (2003) Innominate artery compression of the trachea: an unusual cause of apnea in a 12-year-old boy. *South Med J* 96: 1161-1164.