

Kniest Dysplasia in a Girl Aged 6 Years

Petrasova Sarka¹,
Zemková Daniela^{1,2},
Marik Ivo^{1,3},
Mortier Geert R⁴ and
Kozłowski Kazimierz⁵

Abstract

We report clinical, radiological and anthropological findings from the first Czech patient with Kniest dysplasia whose radio-clinical diagnosis was confirmed by DNA studies. Kniest dysplasia is an inherited disorder associated with defects in type of collagen II with specific clinical and characteristic radiographic findings. Our affected girl had dysmorphic and radiographic features consistent with Kniest disease: cleft palate, hip dysplasia, dysmorphic flat face, short trunk and extremities, spine deformity, platyspondyly, short and broad femoral necks. Mental development was normal. Body height was below norm (-3.2 SD) and muscular hypotrophy of the extremities and trunk was noticeable. Molecular studies supported the diagnosis of Kniest disease by identification of the COL2A1 mutation (c.1023+1G>A) in intron 16.

Keywords: Kniest disease/dysplasia; Spondylo-epi-metaphyseal dysplasia; Collagenopathy type II; Anthropometry

Received: February 03, 2016; **Accepted:** February 09, 2016; **Published:** February 15, 2016

Introduction

Kniest dysplasia is a rare bone dysplasia with suggestive clinical and characteristic radiographic findings.

The major clinical findings are small stature - short trunk with dorsal kyphosis. The final body height ranges from 106 to 145 cm, peculiar face with flat mid-face and depressed nasal bridge. Intellectual development and life expectancy are normal [1].

The major radiographic features are platyspondyly with anterior wedging of vertebral bodies, broad ilia with hypoplasia of basilar portions, very broad and short femoral necks, severe dysplasia and late ossification of the capital femoral epiphyses and short tubular bones with broad metaphyses and large and deformed epiphyses [2].

Differential diagnosis of Kniest disease in early childhood is with other spondylo-epi-metaphyseal dysplasias, particularly Strudwick type and allied disorders. In later childhood Collagen II osteopathies, especially Spondyloepiphyseal dysplasia congenita warrants consideration. Also we have to think on Metatropic dysplasia [1].

Genetics and molecular pathology

The genetic transmission is autosomal dominant. Most of the patients are sporadic, representing new mutations of the determinant gene. The condition is a type 2 collagenopathy

- 1 Ambulant Centre for Defects of Locomotor Apparatus, Prague, Czech Republic
- 2 Paediatric Department, University Hospital Motol, Prague, Czech Republic
- 3 Faculty of Health Studies, West Bohemia University, Pilsen, Czech Republic
- 4 Department of Medical Genetics, Antwerp University Hospital, B-2650 Edegem, Belgium
- 5 Radiological Department of Westmead NSW 2145, Sydney, Australia

Corresponding author: Marik Ivo

✉ ambul_centrum@volny.cz

Head of the Ambulant Centre for Defects of Locomotor Apparatus, Prague, Czech Republic.

Tel: 420222582214

Citation: Petrasova S, Zemkova D, Marik I, et al. Kniest Dysplasia in a Girl Aged 6 Years. J Rare Dis Diagn Ther. 2016, 2:1.

caused by mutations of the COL2A1 gene. Somatic and gonadal mosaicism occur [3].

Course and prognosis

In severe cases, short stature, prominent knees, cleft palate and clubfeet are noted at birth. Chronic otitis media, hearing loss, myopia and retinal detachment are major complications. Joint contractures, spinal deformities and epiphyseal dysplasia with precocious development of osteoarthritis need orthopaedic attention. The patients may lead active lives in spite of their severe handicap.

We report the first Czech patient with Kniest disease whose radio-clinical diagnosis was confirmed by DNA studies.

Case Report

This girl was referred to the Ambulant Centre for Defects of the

Locomotor Apparatus in Prague at the age of 5 years with the diagnosis of an unclassified bone dysplasia.

She was born at term, weight 3350 g, length 48 cm, Apgar scores were 7-8-8. A soft and hard palate cleft were noted after birth. The pregnancy was uncomplicated except for a vaginal bleeding at 5 months for which the mother was hospitalised. No relatives were known to be of short stature or affected by a bone dysplasia. A sister aged 15 months is normal.

At the age of 8 months bilateral hip dysplasia was diagnosed. The palate was repaired at 12 months. Her motor development was delayed and she walked at 18 months. She has been followed by speech therapist. She is hypermetropic and uses spectacles for the whole day. She was treated with Pavlik's harness followed by operation of the right hip at 18 months and left hip at 24 months. A fracture in the distal part of the left femur occurred after a fall at the age of 3 years, and a supracondylar fracture of the right femur after a car accident at the age of 5 years.

Physical examination at the age of 5 years revealed shortening of the trunk and the extremities. The girl had a dysmorphic flat face with hypertelorism, a small nose with a depressed nasal bridge, anteverted nostrils, down turned mouth corners and a thin upper lip. The teeth of the upper jaw were small and carietic. Her ears were low set and her hair was normal (**Figure 1A**). In the spine there was loss of thoracic kyphosis associated with lumbo-sacral hyperlordosis and a mild sinistro-scoliosis of the thoracic and lumbar regions. All the joints were prominent with limitation of the movements. There was valgus deformity of the knees and noticeable muscular hypotrophy. Bilateral clinodactyly of the 5th fingers and a simian crease in the left hand were other features (**Figures 1B and 1C**). The girl walked with short steps with semi-flexion of the knees and hips. Her mental development was normal.

Anthropological examination

Anthropological examination at the age of 6 year:

Body height: 100.8 cm - under the 3rd percentile (-3.24 SD). Growth velocity 4.7 cm/year (6. P) – growth retardation in comparison with the examination findings at 5 years of age.

Weight: 14.7 kg (-2.82 SD). Weight to height was in the normal range (24. P), Body Mass Index 14.5 (-0.52 SD, i.e., 26. P), but skinfold thickness was below average and the mid-arm circumference was below standard 14,8 cm (-2,31 SD) confirming muscular hypotrophy. Antropometric measurement proved higher robusticity of the skeleton especially at upper extremities (humeral epiphysis 2.1 SD, femoral epiphysis 1.29 SD).

Sexual maturation: Prepubertal (P1, M1).

Proportionality: Shortening of the trunk and extremities. Sitting height 56 cm below norm (-3.17 SD), subsischial length of lower extremities below norm 44.8 cm (-2.74 SD), trunk/extremities ratio 125% (1,5 SD) shows borderline shortening of lower extremities in relation to the height of the trunk. Shortening of upper extremities, arm span 103 cm (-2.6 SD) (**Figure 2**). Narrow transversal diameter of thorax 15.8 cm (-1.99 SD), sagittal

diameter of thorax is normal 13.6 (0.85 SD) - barrel-shaped chest.

Cephalometry: Circumference of head 50 cm, normal, hyperbrachycephaly.

Auxological summary: Significant shortening of upper and lower body segments. Extremities are more affected than the trunk. Growth failure is significant in comparison both with healthy population and the midparent height (mother 157 cm, father 176.5 cm). She is underweight, with a mild truncal deformity.

Radiological examination

Radiological examination at the age of 5 years documented generalised skeletal changes which were consistent with Kniest dysplasia (**Figures 3A-3F**).

Densitometric examination

Densitometric examination DXA (Hologic Discovery A, S/N 85046) was carried out at the age of 7 years. The BMD of both femurs and the whole body corresponded to a low bone mass for the chronological age.

BMD of lumbar spine – Z-score total: -1.7

BMD of the left femur - Z-score total: -3.9

BMD of the right femur - Z-score total: -3.3

BMD of the whole body (Z-score total: -3.0)

Body composition: total body % fat: 23.4

In 9 years of age repeated DXA examination proved an increase of the whole body BMD about 12.8% (**Figure 2**) and lumbar spine BMD on 10.8%.

The routine blood and urine examinations

The routine blood and urine examinations at the age 5 years were all normal, serum calcium 2.4 mmol/l (normal range 2.2-2.7), phosphorus 1.44 mmol/l (normal range 1.10-1.90) and markers of bone turnover: bone alkaline phosphatase – bALP 1.37 μ kat/l (normal range 1.35–2.69), osteocalcine - OC 30.0 μ g/l (normal range 26.1–63.5), carboxyl-terminal telopeptide of collagene type I – CTX 0.496 ng/ml (normal range 0.142–0.522).

Serum 25-hydroxyvitamin D - vitamin D level was decreased 29.2 nmol/l (normal range 47.7-144.0). Normal level of parathormone – PTH 29.0 pg/ml (normal range 8.8–76.6).

Genetic examination

The family history was negative. The affected girl represented an isolated case in the family. Karyotype 46, XX, 14ps+.

Molecular studies

Supported the diagnosis of Kniest disease by identification of the COL2A1 mutation (c.1023+1G>A) in intron 16 (Department of Medical Genetics, Antwerp University Hospital, B-2650 Edegem, Belgium).

Discussion

Kniest disease is a rare spondylo-epi-metaphyseal dysplasia with

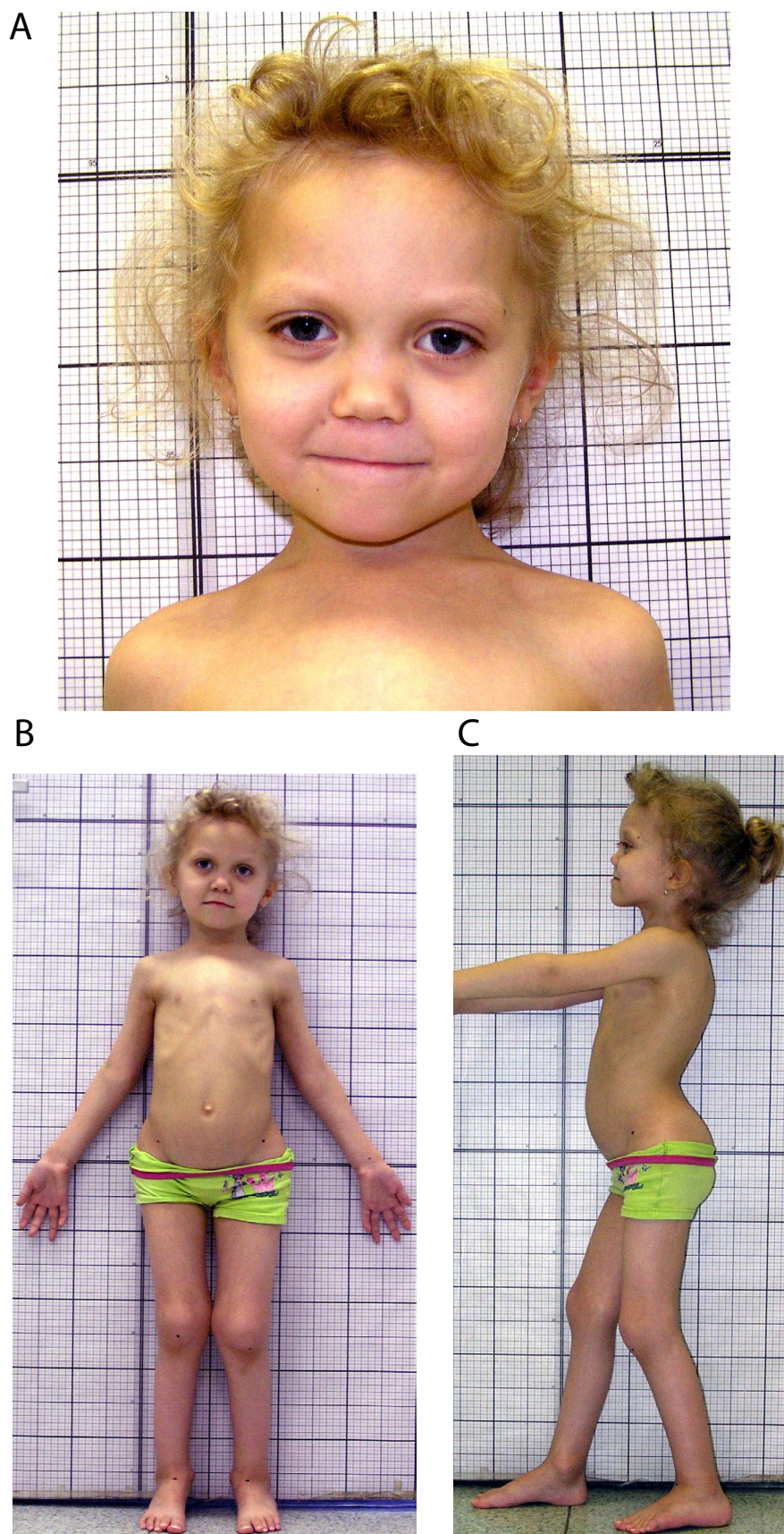
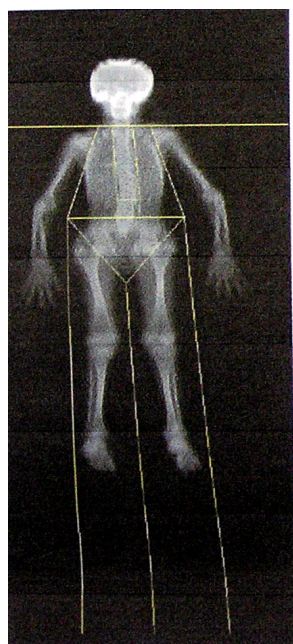


Figure 1 The patient aged 6 years.

A: A dysmorphic face with hypertelorism and a flattened nasal bridge. **B, C:** Short stature. Height 100.8 cm (-3.42 SD), weight 14.7 kg (-2.82 SD), sitting height 56 cm (-3.17 SD), arm span 103 cm (-2.6 SD). Prominent knees. Thoracic kyphosis and hyperlordosis.



327 x 150
DAP: 13.1 cGy*cm²

Scan Date: 02 July 2014 ID: A0702140A
Scan Type: a Whole Body
Analysis: 02 July 2014 12:13 Version 13.1.2
Auto Whole Body Fan Beam
Operator: ZS
Model: Discovery A (S/N 85046)
Comment:

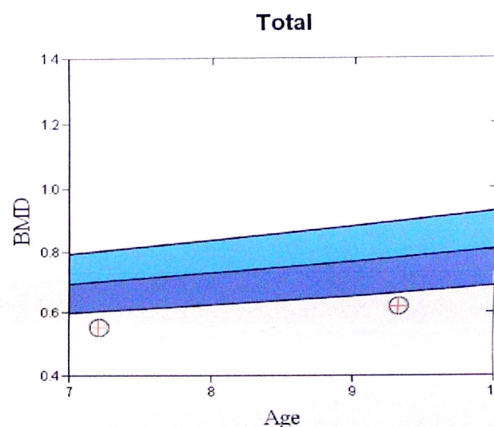


Figure 2 Whole body scan of the patient, 9 years of age. An increase of the whole body BMD about 12.8% was proved in comparison with examination at 7 years. Total body fat was 22.9% (i.e., 5th percentile of American population), lean mass/height² 10.2 kg/m² (i.e., 4th percentile of American population).

suggestive dysmorphism and a characteristic radiographic pattern [1].

The dysmorphic features consist of a flattened nasal bridge, hypertelorism and a small jaw. A short trunk with kyphosis, short extremities with prominent joints and restricted mobility are distinctive features which are present in the first few years of life. Cleft palate, myopia and hearing loss occur in up to 50% of affected individuals [1].

Identification of Kniest disease is more difficult in new-borns and infants as some characteristic manifestations are age-related. There is a progression of bone contractures and spine deformities during the growth. In a dysmorphic child with short stature and cleft palate the diagnosis of Kniest disease should be considered. Coronal clefts in the vertebral bodies are an important radiographic sign for the early diagnosis [2].

The representative radiographic findings consist of hypoplasia of the facial bones, platyspondyly with anterior wedging of the vertebral bodies, shortened sacro-iliac notches, short femoral necks, late appearing or absent capital femoral epiphyses, broad metaphyses particularly those of the femoral neck, large knee epiphyses and dysplastic epiphyses of the short tubular bones. Pseudo-epiphyses of the metacarpals are – if present – a significant diagnostic indicator of Kniest disease.

Diferential Diagnosis

The diferential diagnosis of Kniest disease in early childhood is with other spondyloepimetaphyseal dysplasias, particularly Strudwick type [4] and allied disorders [5]. In later childhood

Collagen II osteopathies, especially spondyloepiphyseal dysplasia congenita (Spranger-Wiedemann disease) [6] warrant consideration. Both have dysmorphic faces, while myopia and cleft palate may be present. Radiographic differences in these disorders are the greater severity of the hip changes and more advanced epiphyseal abnormalities in Kniest disease. On the other hand, patients with Kniest dysplasia are slightly higher than those with SED [7]. Molecular investigations are useful in early childhood and in doubtful cases.

Kniest disease is inherited as an autosomal dominant trait but most of the patients are sporadic, representing new mutations of the determinant gene. The condition is a type 2 collagenopathy caused by mutations of the COL2A1 gene [8]. The differences in the severity of the clinical course are due to intramolecular heterogeneity. Somatic mosaicism is another possibility. The final body height ranges from 106 to 145 cm, growth of our patient is in this range.

Conclusion

The authors present the first Czech patient with Kniest dysplasia whose radio-clinical diagnosis was confirmed by DNA studies. The affected girl had dysmorphic and radiographic features which were consistent with this diagnosis. The final height will be probably between 130 and 140 cm.

Acknowledgement

Authors thank the parents of the presented proband for close cooperation during repeated examination and treatment and their consent to publish indispensable photos.

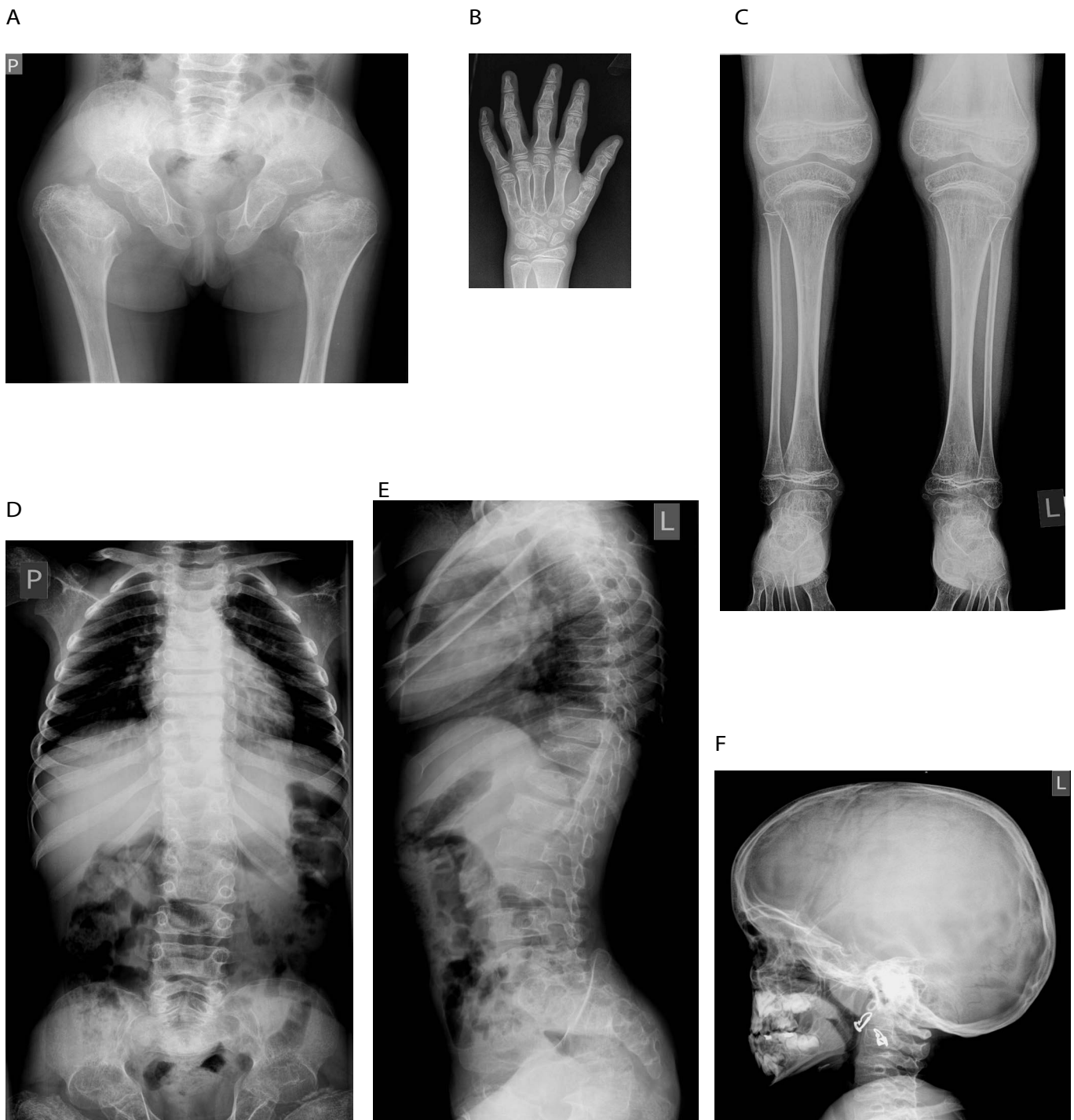


Figure 3 X-rays of the patient, 5 years of age.

A: Pelvis and hips. The pelvis is small. The basilar portions of the iliac wings are shortened. The femoral necks are very broad and very short. The capital femoral epiphyses are very small and dysplastic. The left capital femoral epiphysis is flattened. **B:** Left hand. There is shortening of the tubular bones most marked distally. The first metacarpal is short and broad and the metaphyses of the tubular bones are widened. The epiphyses are flattened and slightly deformed. The carpal bones are abnormal in shape. A small supernumerary bone is present between the os navicularis and os lunatum. The distal femoral epiphyses are flattened. **C:** Knees and legs. The epiphyses are slightly flattened. The distal femoral epiphyses are large. The proximal tibial metaphyses are bowed superiorly. The fibulae are thin and shortened proximally. **D, E:** Spine A-P and lateral. There is generalized platyspondyly with slight anterior wedging of the thoracic vertebrae. The lumbar spinal canal is relatively wide. **F:** Skull. The cranium is large in relation to the face, and there is hypoplasia of the facial bones. The upper facial bones are more severely affected.

References

- 1 Spranger JW, Brill PW, Poznanski A (2002) Bone Dysplasias. An Atlas of Genetic Disorders of Skeletal Development: Kniest Dysplasia. Oxford University Press 155-159.
- 2 Kozlowski K, Beighton P (2001) Gamut index of skeletal dysplasias: An Aid to Radiodiagnosis. Springer, Verlag London.
- 3 Mortier GR, Wilkin DJ, Wilcox WR, Rimoin DL, Lachman RS, et al. (1995) A radiographic, morphologic, biochemical and molecular analysis of a case of achondrogenesis type II resulting from substitution for a glycine residue (Gly691-to-Arg) in the type II collagen trimer. Hum Molec Genet 4: 285-288.
- 4 Tiller GE, Polumbo PA, Weiss MA, Bogaert R, Lachman RS, et al. (1995) Dominant mutations in the type II collagen gene, COL2A1, produce spondyloepimetaphyseal dysplasia, Strudwick type. Nat Genet 11: 87-89.
- 5 Spranger J, Winterpracht A, Zabel B (1997) Kniest dysplasia: Dr. W. Kniest and his patient, the molecular defect. Am J Med Genet 69: 79-84.
- 6 Spranger JW, Brill PW, Poznanski A (2002) Bone Dysplasias-An Atlas of Genetic Disorders of Skeletal Development: Spondyloepiphyseal Dysplasia Congenita. Oxford University Press 160-167.
- 7 Horton WA, Hall JG, Scott CI, Pyeritz RE, Rimoin DL (1982) Growth curves for height for diastrophic dysplasia, spondyloepiphyseal dysplasia congenita and pseudoachondroplasia. Am J Dis Child 136: 316-319.
- 8 Spranger J, Winterpracht A, Zabel B (1994) The type II collagenopathies: a spectrum of chondrodysplasias. Eur J Pediatr 153: 56-65.