

Isolated and Syndromic Congenital Sternal Cleft

Anne Dupré la Tour²,
François Varlet¹,
Hugues Patural² and
Manuel Lopez¹

Abstract

Purpose: Sternal cleft is a rare congenital anomaly of chest wall deformities, caused by the failure of fusion of the sternal elements that can expose mediastinal viscera and vessels to injuries. It can be classified into two forms, partial and complete sternal cleft. The etiology and incidence are unknown and it is often associated with other defects. We report our experience in the treatment of sternal abnormalities and we consider results and evolutions.

Methods: From 1994 to 2015, we reviewed the charts of 5 neonates (4 females and 1 male) with sternal anomalies. The mean weight at birth was 3,2kg (2.2-4.1). The diagnosis was realized at birth (four cases), and prenatally (one case). The sternal defects implied two upper, two lower and one total sternal cleft. Associated abnormalities were seen in four cases (two PHACES syndrome, and two Cantrell's Pentalogy).

Results: Surgical correction was performed in 3 of them. In cases of upper sternal cleft, primary closure was performed at 5 and 10 week-old respectively. In complete sternal cleft, prosthetic closure was done at 14 days old, and the primary repair was made seven months later. No repair was necessary in the inferior sternal cleft. No complications were reported. The mean follow-up period was 9.5 years (3.6-21 years). All patients achieved good functional and cosmetic results after surgical correction.

Conclusion: Primary closure is the preferred option and should be performed in the neonatal period. The use of prostheses warrants good results for patients with a great distance between the sternal halves. Even for asymptomatic patients, sternal surgery is necessary to offer physical protection of the heart and to prevent recurrent respiratory infections due to the paradoxical respiratory movements. In some cases, surgical correction could be unnecessary, particularity in lower defects.

Keywords: Sternal cleft; PHACES syndrome; Cantrell's Pentalogy; Paediatrics

- 1 Pediatric Surgery Department, North Hospital, Saint-Etienne University Hospital Center, F-42023 Saint-Etienne, France
- 2 Pediatric Department, North Hospital, Saint-Etienne University Hospital Center, F-42023 Saint-Etienne, France

Corresponding Author:

Manuel Lopez

Pediatric Surgery Department, North Hospital, Saint-Etienne University Hospital Center, F-42023 Saint-Etienne, France.

✉ Manuel.lopez@chu-st-etienne.fr

Tel: 0477828847

Citation: ADL Tour, Varlet F, Patural H, et al. Isolated and Syndromic Congenital Sternal Cleft. J Rare Dis Diagn Ther. 2015, 1:3.

Received: November 01, 2015; **Accepted:** November 14, 2015; **Published:** November 21, 2015

Introduction

Chest wall malformations represent a large phenotypic spectrum. Among them, congenital sternal clefts are rare abnormalities, and have been classified as complete (the rarer form) or incomplete. The incidence is of 1:100,000 cases per live birth, and represents about less than 1% of all chest wall deformities [1].

In embryonic life, the sternum is derived from the lateral plate mesoderm of either side of midline, which becomes fused during the 10th weeks. The sternum development appears during the 6th week of embryology as a pair of condensed and parallel

mesenchymal bands. Cells migrate from two lateral plates on either side of the anterior chest wall to fuse in the midline in a craniocaudal fusion. The original sternum is cartilaginous then multiple ossification centers develop in a craniocaudal sequence (**Figure 1**). This anomaly results from a failure fusion of the sternum. Very rarely, the sternal bars fail to join in the midline, which results in a complete or incomplete sternal cleft. The clinical severity of sternal cleft ranges from the benign sternal cleft to the potentially lethal *ectopia cordis*. Generally sternal cleft is observed at birth. The prognostic depends mostly on associated abnormalities as congenital cardiac diseases. It

leads to severe cardiovascular disturbance during anesthesia particularly when pulmonary hypertension is associated [2]. Sternal cleft may be associated also with defects in the anterior chest wall such as *ectopia cordis*, or Cantrell's pentalogy, with a combination of defects involving the abdominal wall, sternum, diaphragm, pericardium and heart, possibly diagnosed prenatally with three-dimensional ultrasonography.

Surgery is indicated to protect the heart and major vessels, of injuries by external trauma. It improves respiratory dynamics and esthetics. The challenge to the anesthetist is the risk of paradoxical respiration especially if the defect is incomplete.

We report our experience in the treatment of sternal abnormalities and we discuss the results and evolutions of these patients.

Materials and Methods

From 1994 to 2015, we reviewed five cases of neonatal sternal defects. The majority of patients were girls (4:1). Four cases were discovered at birth and one prenatally and confirmed by MRI. The mean weight at birth was 3,2kg (2.2-4.1). Sternal abnormalities types were:-Upper sternal cleft in two cases; one case isolated abnormality, and the other associated with PHACES syndrome (posterior fossa brain malformations, facial hemangiomas, arterial anomalies, cardiac defects, eyes abnormalities, sternal cleft, and supra umbilical raphe) -Lower sternal cleft in two cases; one associated to PHACES syndrome (**Figure 1**), intestinal atresia and gyral pattern disorders. The other abnormality associated as part of a field defect known as Cantrell's Pentalogy (*ectopia cordis*, deficiency of the anterior diaphragm, supra umbilical abdominal wall defect, defect in lower sternum, and congenital intra-cardiac abnormalities) -One total sternal cleft associated with Cantrell's pentalogy. Characteristics of patients are reported in the **Table 1**.

All patients were studied preoperatively by chest X-ray, computerized tomography, cardiologic evaluation, genetic evaluation. When the sternal abnormality was associated to hemangiomas, cerebral MRI and ophthalmic evaluation were done (**Figure 2**).

In three cases, surgical correction by primary closure was done (two upper and one complete). These patients presented retraction at the defect with inspiration and protrusion with exhalation or Valsalva maneuver.

During surgery, a cerebral and splanchnic monitoring was evaluated with the use of near infrared spectroscopy (NIRS). Postoperatively, all infants were admitted to the neonatal intensive care unit.

Surgical approach

Under endo-tracheal general anesthesia, the patient was placed in decubitus position, the skin incision was vertical on the midline (**Figure 3**), and the pectoral muscles were dissected to expose the sternal bars and then, the medial edges of the two sternal halves were freed from the underlying pleura and pericardium. The inferior aspect of partial sternal cleft was incised, when U shaped, to make closure easier. The sternal bars were approximated on the midline by non-absorbable sutures (**Figure 4**).

If complete sternal cleft was too wide or there was a mediastinal compression after sternal bar juxtaposition, we closed the defect by placing non-absorbable prostheses in multiple layers and then, the defect and the primary repair was delayed using the technique described previously.

Results

Surgical correction was performed in 3 of them. During primary closure, none signs of compression of the mediastinum appeared. None intra-operative complications occurred. Near infrared spectroscopy indices stayed normal and regular all along the surgeries. Mean operative time was 120 min (100-150). In cases of upper sternal cleft, primary closure was performed at 5 and 10 week-old respectively. In complete sternal cleft, prosthetic closure was done at 14 days-old, and the primary repair was done seven months later. In cases of lower sternal cleft non-surgical

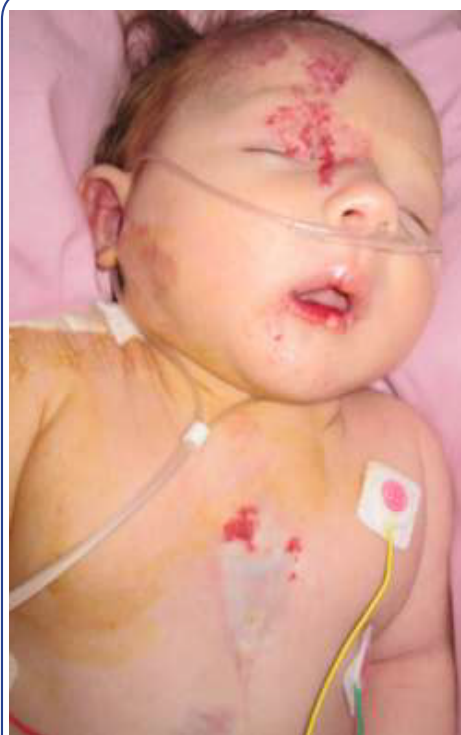

Figure 1 Facial and thoracic hemangiomas and superior sternal cleft with supraumbilical raphe.

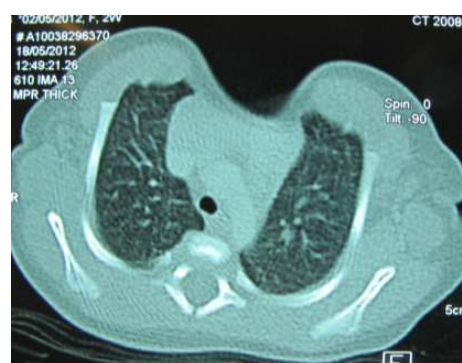

Figure 2 CT-scan in superior sternal cleft.

correction was necessary due to asymptomatic patients and minor defect.

The mean follow-up period was 9.5 years (3.6-21 years). No complications were reported. All patients achieved good functional and cosmetic results after correction.

Discussion

Sternal cleft malformation is caused by a fusion failure of the sternal elements. The aetiology is unknown, thought to arise from a failure of ventral fusion of the sternal bars during the 8th week of gestation. There is a female predominance. Alcohol intake and methylcobalamine or riboflavine deficiency is associated with sternal cleft, and studies in mice indicate abnormalities in HOX b gene expression as a possible factor [3].

Sternal diagnosis is prenatally difficult with ultrasonography. Twomey considers this abnormality as a thinned and sunken midline anterior chest wall with intact skin coverage but no identifiable cartilaginous sternum [4].

Sternal clefts are classified as being total or partial. The partial malformation can be superiorly or inferiorly located, with the upper sternum being the most common and almost always isolated abnormality [5]. Occasionally it can be associated with PHACES syndrome [6]. The rare inferior variety is often associated

with a thoraco-abdominal *ectopia cordis*, being part of a Cantrell's Pentalogy [7].

Superior clefts have orthotopic normal heart, normal skin coverage, and intact pericardium. With isolated cleft, the patient is usually asymptomatic, except during cries or coughs (upper and midline thoracic depression during inspiration and a prominence during expiration) [1]. When a sternal cleft is diagnosed, associated anomalies must be searched by careful physical examination, chest X-ray and echocardiography, because the prognostic changes if the cleft had associated abnormalities. Genetic evaluation can be useful [6].

When haemangioma was associated, other criteria's of PHACES syndrome must be searched and then, a cerebral RMI and an ophthalmologic evaluation are completed. A consensus statement on diagnostic criteria was published in 2009 [6].

Regarding Cantrell's Pentalogy, the prognosis depends mainly on the cardiac abnormalities [7].

Even for asymptomatic patients, sternal surgery is necessary to offer protection to the heart, to prevent recurrent respiratory infections due to paradoxical respiratory movements, to maintain the growth potential of the chest wall and to offer a good cosmetic outcome. Chest computerized tomography or MRI is preoperatively required to confirm the presence of a sternal cleft and establish the type (presence or not of bar inferiorly) and then to plan the surgery [8].

Surgical correction is indicated to protect the heart and major vessels, to improve respiratory dynamics and aesthetic profile. Only in very minor defects, particularly in lower sternal cleft, conservative treatment can be propose for asymptomatic patients. In our series, in two cases of lower sternal cleft, non-surgical correction was done with uneventful course.

The patient age is an important factor for primary repair, preconized if possible in the neonatal age to achieve primary closure. In some cases the reduction in thoracic volume can cause cardiovascular impairment. It is validated that after 3 months of age, the chest wall becomes relatively rigid and more complicated techniques may be required such as use of prostheses, partial or total thymectomy, sliding chondrotomies, and clavicle dislocation. These techniques can be an alternative to primary closure if the latter is challenging or impossible due to a stiff thorax [1].

For patients 1 and 2, sternal surgery was accomplished respectively at 10 weeks and 40 days, by primary closure alone. For patient 4, primary closure was impossible at 14 days because of a great distance between the sternal halves. A prosthetic material was necessary, and direct approximation of the sternal halves was performed at 7 months.

Many authors agree to say that primary repair is best accomplished in the neonatal period, benefiting from of the pliability of the chest wall and less compression of underlying structures. If signs of mediastinum compression appear during surgery, primary repair should be terminated for a more elaborate approach (sliding or rotating chondrotomies, pectoralis major myoplasty, clavicular fracture, or even autologous tissue flaps, myocutaneous flaps, prosthetic materials) [5,8,9].

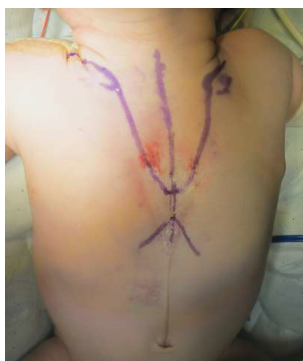

Figure 3 Vertical incision on the midline and anatomic marks.

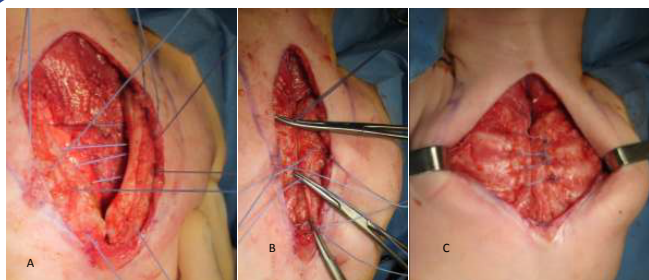


Figure 4 Surgical correction of sternal defect.

- A. Exposition of sternal bars: The medial edges of the two sternal halves were freed from the underlying pleura and pericardium.
- B. Sternal bars are re-approximated.
- C. Primary closure

Table 1. Data base of patients (ICA: internal carotid artery; ACA: Anterior Cerebral Artery; PCA: Posterior Cerebral Artery).

PATIENTS	1	2	3	4	5
Year of birth	2007	2012	2012	1994	2004
Prenatal diagnosis	no	No	no	no	yes
Sex (male/female)	M	F	F	F	F
Gestational weeks (WG)	38	40	40	39	38
Birth weight (g)	2200	3300	2810	3450	4184
Associated Syndrome	Isolated sternal cleft	PHACES	PHACES	Cantrell's Pentalogy	Cantrell's Pentalogy
Type of cleft	Superior	Superior	Inferior	Total	Inferior
Phenotype		Large frontotemporal segmental facial hemangioma, abdominal and thoracic hemangiomas, hypoplasia of the right ACA, supraumbilical raphe, optic nerve hypoplasia	Large left and right frontotemporal segmental facial hemangiomas, parotid hemangioma, ventricular septal defect, right aortic arch, agenesis of vertebral and basilar arteries, hypoplasia of the right ICA, agenesis of the right ACA and PCA, aberrant origin of the left ACA and PCA, sclerocornea, supraumbilical raphe, congenital ulcerations on nose and ears	Small omphalocele, anterior pericardial defect	Large omphalocele, anterior diaphragmatic defect
Associated anomalies	Atrial septal defect		Jejunal atresia, gyration disorders		Complete common mesentery
Sternal surgery	10 weeks: Primary closure alone	40 days: Primary closure alone	No	Prosthetic closure at 14 days, primary closure at 7 months	No
Follow-up	8 years and 6 months: Asymptomatic	3 years and 10 months: Good evolution with propanolol for hemangiomas, normal neurodevelopment	3 years and 6 months: Ulcero-necrotizing enterocolitis, ileostomy, digestive haemorrhage, digestive angiomatosis, treatment with propanolol, seizures controlled by antiepileptic, normal neurologic examination	Bronchial hyperreactivity, gastroesophageal reflux disease, new surgery at 25 months (upper sternal closure and muscle plastic surgery). Adult: Sports with beta2-adrenergic receptor agonist, good esthetic outcome	Omphalocele surgery, gastroesophageal reflux disease. At 9 years, inferior sternal defect at palpation, asymptomatic

In conclusion, congenital sternal clefts are uncommon pathologies and require a multidisciplinary approach to optimize the patient's outcome. They can be isolated or part of a syndrome, justifying complementary explorations. The surgical approach is not required for all patients. Surgical treatment depends on the

type of sternal malformation. Best results are obtained during the neonatal period, when the chest wall is maximally flexible to make the repair easier. Furtherer, if necessary, a prosthetic closure can resolve the malformation in better conditions.

References

- 1 Fokin AA (2000) Cleft sternum and sternal foramen. *Chest Surg Clin N Am* 10: 261–276.
- 2 Saha AK, Sardar SK, Sur A (2013) Congenital sternal cleft along with persistent left-sided superior vena cava: A rare presentation. *Case Rep Pediatr* 2013: 192478.
- 3 Engum SA (2008) Embryology, sternal clefts, ectopia cordis, and Cantrell's pentalogy. *Semin Pediatr Surg* 17: 154-160.
- 4 Twomey EL, Moore AM, Ein S, McAuliffe F, Seaward G, et al. (2005) Prenatal ultrasonography and neonatal imaging of complete cleft sternum: a case report. *Ultrasound Obstet Gynecol* 25: 599-601.
- 5 Acastello E, Majluf R, Garrido P, Barbosa LM, Peredo A (2003) Sternal cleft: a surgical opportunity. *J Pediatr Surg* 38: 178-183.
- 6 Metry D, Heyer G, Hess C, Garzon M, Haggstrom A, et al. (2009) Consensus statement on diagnostic criteria for PHACE syndrome. *Pediatrics* 124: 1447-1456.
- 7 Vanamo K, Sairanen H, Louhimo I (1991) The spectrum of Cantrell's syndrome. *Pediatr Surg Int* 6:429-433.
- 8 Torre M, Rapuzzi G, Carlucci M, Pio L, Jasonni V (2012) Phenotypic spectrum and management of sternal cleft: literature review and presentation of a new series. *Eur J Cardiothorac Surg* 41:4-9.
- 9 Yamanaka K, Higuma T, Watanabe K, Okada Y, Ichida F, et al. (2012) Congenital sternal cleft. *J Pediatr Surg* 47: 2143-2145.